Acute myeloid leukaemia (AML) harbouring *KMT2A*-PTD: should it be considered as a myelodysplasia-related abnormality?

Narasimhapriyan Kannan ,[1,2] Aarti Achrekar,[1] Vishram Terse,[1] Vaibhav Gawde,[1] Swapnali Joshi,[1] Prasanna Bhanshe,[1] Shruti Chaudhary,[1] Pratiksha Salunke,[1] Sitaram Ghogale,[1] Nilesh Deshpande,[1] Dhanlaxmi Shetty ,[3] Alok Shetty,[2,4] Sumeet Mirgh,[2,4] Lingaraj Nayak,[2,4] Anant Gokarn,[2,4] Sachin Punatar,[2,4] Hasmukh Jain,[2,4] Bhausaheb Bagal,[2,4] Manju Sengar,[2,4] Navin Khattry,[2,4] Sweta Rajpal,[1,2] Gaurav Chatterjee,[1,2] Prashant Tembhare,[1,2] Papagudi G Subramanian ,[1,2] Nikhil Patkar [1,2]

► Additional supplemental material is published online only. To view, please visit the journal online (https://doi.org/10.1136/jcp-2025-210460).

[1]Department of Haematopathology, ACTREC, Navi Mumbai, India
[2]Homi Bhabha National Institute, Mumbai, India
[3]Department of Cytogenetics, ACTREC, Navi Mumbai, India
[4]Adult Haematolymphoid Disease Management Group, Tata Memorial Centre, Mumbai, India

Correspondence to
Dr Nikhil Patkar; nvpatkar@gmail.com

Received 1 October 2025
Accepted 1 March 2026

Check for updates

© Author(s) (or their employer(s)) 2026. No commercial re-use. See rights and permissions. Published by BMJ Group.

To cite: Kannan N, Achrekar A, Terse V, *et al*. *J Clin Pathol* Epub ahead of print: [*please include* Day Month Year]. doi:10.1136/jcp-2025-210460

ABSTRACT

Aims Although acute myeloid leukaemia (AML), myelodysplasia-related (AML-MR), can be defined solely by molecular abnormalities, legacy studies did not analyse the *KMT2A* gene. The *KMT2A*-partial tandem duplication (*KMT2A*-PTD) is described in myelodysplastic neoplasms (MDS) as well as AML. We describe the clinical, morphological, immunophenotypic and molecular features of AML harbouring *KMT2A*-PTD.

Methods We studied 802 adult AML patients, for whom next-generation sequencing- based mutation and copy number analysis were available. For the patients harbouring *KMT2A*-PTD, the immunophenotypic analysis including measurable residual disease (MRD), mutational landscape and the patient outcomes were analysed.

Results We identified 45 patients of de novo and secondary AML harbouring *KMT2A*-PTD. Morphological dysplasia and immunophenotypic abnormalities, described in MDS, were observed in 35.6% and 40% of de novo cases respectively. Furthermore, 44% of AML with *KMT2A*-PTD could be diagnosed as AML-MR based on cytogenetics or genomics. We observed progenitor abnormalities, commonly aberrant CD7 (33%) and CD15 (59%), and granulocytic abnormalities like loss of side scatter (50%), asynchronous maturation patterns and loss of CD177 in mature granulocytes. Frequent mutations involving *IDH2* (30% of which were R172), *FLT3* (32% each), *RUNX1* (29%), *DNMT3A* and *U2AF1* (24% each) were noted. We also found that more than 25% of patients did not achieve morphological remission, and the remaining 60% were MRD positive. The outcomes of AML with *KMT2A*-PTD with or without MR-associated abnormalities were similar.

Conclusions AML harbouring *KMT2A*-PTD frequently displays MR immunophenotypic abnormalities and is frequently associated with AML-MR type mutations. In addition, they have similar outcomes as compared with AML-MR.

WHAT IS ALREADY KNOWN ON THIS TOPIC

⇒ Although *KMT2A*-partial tandem duplication (PTD) is not infrequent and has prognostic relevance in myelodysplastic neoplasms and acute myeloid leukaemia (AML), current classification schema do not consider its role in the ontogeny of secondary AML.

WHAT THIS STUDY ADDS

⇒ We demonstrate *KMT2A*-PTD in de novo as well as secondary AMLs. There is a presence of morphologic and immunophenotypic dysplasia in nearly half the cases of de novo AML harbouring *KMT2A*-PTD, and they are enriched in AML-myelodysplasia-related (MR)-associated genetic abnormalities.

HOW THIS STUDY MIGHT AFFECT RESEARCH, PRACTICE OR POLICY

⇒ We propose recognising *KMT2A*-PTD as an AML, MR-defining abnormality.

INTRODUCTION

The *KMT2A* (Lysine-specific histone N-methyltransferase 2A) gene (previously known as mixed lineage leukaemia, *MLL gene*) is involved in transcriptional activation and regulation of haematopoiesis by maintaining the expression of *HOX* genes as well as other targets.[1] Chromosomal rearrangements involving the 11q23 locus (harbouring the *KMT2A* gene) are frequently associated with infantile, paediatric and adult de novo as well as therapy-associated leukaemia. The *KMT2A* recombinome is diverse with more than a hundred fusion partners described thus far.[2] *KMT2A* rearrangements are associated with inferior outcomes and are described as an adverse risk abnormality (except for the *KMT2A::MLLT3* fusion) in the European Leukemianet (ELN) 2022 risk stratification for acute myeloid leukaemia (AML).[3]

Partial tandem duplications (PTDs) of the *KMT2A* gene have also been described in literature, especially in myeloid malignancies such as myelodysplastic neoplasms (MDS) and AML.[4 5] Although PTDs themselves are not sufficient to develop spontaneous leukaemia, they act as an oncogenic driver by modulating the expression of the *HOX* gene and therefore have a potential

J Clin Pathol: first published as 10.1136/jcp-2025-210460 on 12 March 2026. Downloaded from http://jcp.bmj.com/ on March 12, 2026 at Duke University Medical Center Library. Protected by copyright, including for uses related to text and data mining, AI training, and similar technologies.

therapeutic implication with menin inhibitors.[6–8] The PTD result from small intragenic in-frame insertions at the N terminal of the *KMT2A* gene with breakpoints usually involving introns flanking exons 2 to 8 or 10, often facilitated by Alu elements.[4 7 9 10] Various studies have described that *KMT2A*-PTDs are detected in AML at a frequency of 4%–10% and confer inferior outcomes.[4 9–13]

The *KMT2A*-PTD is a cryptic aberration and therefore cannot be detected by conventional karyotyping or even FISH (Fluorescence in situ hybridisation). Legacy approaches to identify the *KMT2A*-PTD have used reverse transcription-based PCR. This requires a lesion-specific approach and may hinder broad applicability and widespread usage.[4 10–12 14 15] Contemporary approaches to *KMT2A*-PTD detection include multiplex-ligation probe amplification, optical genome mapping and next-generation sequencing (NGS). Among these, NGS has now become a standard-of-care testing for AML, as one can simultaneously detect mutations and copy number variations (CNV) in a single assay, especially with capture-based target enrichment.[16]

There is a paucity of literature with respect to the *pathology* aspects of AML harbouring *KMT2A*-PTD such as the immunophenotype of abnormal blasts as well as granulocytes. A detailed literature search revealed that Shiah *et al* have described CD11b expression in AML harbouring *KMT2A*-PTD.[10] We observed that Choi *et al* have found no difference in immunophenotyping between MDS with *KMT2A*-PTD and MDS without it.[17] Here we investigated if morphological and immunophenotypic features of MDS are present in de novo AML with *KMT2A*-PTD. We also elaborate on the mutational landscape of AML patients with *KMT2A*-PTD and its correlation with myelodysplasia-related (MR) mutations described in the fifth edition WHO classification of haematolymphoid tumours (WHO HAEM5).[18]

METHODS

This was a single-centre, retrospective cohort study done in the department of haematopathology, ACTREC, Tata Memorial Centre, Navi Mumbai. (IEC III: project 901193). A total of 802 adult patients (age 18 years or above) diagnosed to have AML by morphology and immunophenotyping, for whom NGS-based mutation and copy number analysis information was available, were included in the study (2015–2024).

Morphology and immunophenotyping

Diagnosis of AML and assessment of dysplasia in myeloid, erythroid and megakaryocytic lineages in bone marrow (BM) aspirate smears were as per the WHO HAEM5 recommendations.[18] Details of morphology and immunophenotyping are seen in online supplemental Tables 1 and 2. Immunophenotypic granulocytic abnormalities could be evaluated in 35 (out of 39 cases), and erythroid abnormalities in five cases.

Flow cytometry-based measurable residual disease

Measurable residual disease (MRD) analysis was done at the end of induction/first cycle of chemotherapy using a previously described 10-colour two-tube MRD assay or a 16-colour single-tube MRD assay in patients achieving complete remission (CR) or CR with incomplete haematologic recovery (CRi) (online supplemental Table 3).[3 19–23] This approach uses a combination of leukaemia-associated immunophenotype and difference from normal approaches to detect MRD in AML. Both assays were validated with limit of blank, limit of detection and limit of quantification experiments and any value of abnormal myeloid blasts was considered as detection of residual disease.

NGS and PCR

Details of sequencing and bioinformatics are seen in online supplemental Table 4. Additionally, PCR for evaluation of *FLT3*-ITD using fragment length analysis was performed as previously described.[19 21]

Copy number analysis

CNVkit (V.0.9.9) in targeted mode was used to identify copy number alterations using a depth of coverage based principle using a pool of normal samples as a reference (figure 1).[24] Chromosomal level copy alterations detected by CNVkit were validated in our centre with FISH/karyotyping. Intragenic deletions and amplifications (eg, *IKZF1*) were validated using PCR (data not shown). *KMT2A*-PTDs were detected using CNVkit if the $\log_2$ values were more than 0.5 for the corresponding exons of the *KMT2A* gene.[25 26]

To validate the presence of *KMT2A*-PTD, two cases were subjected to targeted RNA sequencing with a myeloid panel containing the *KMT2A* gene (online supplemental Figure 1).[27]

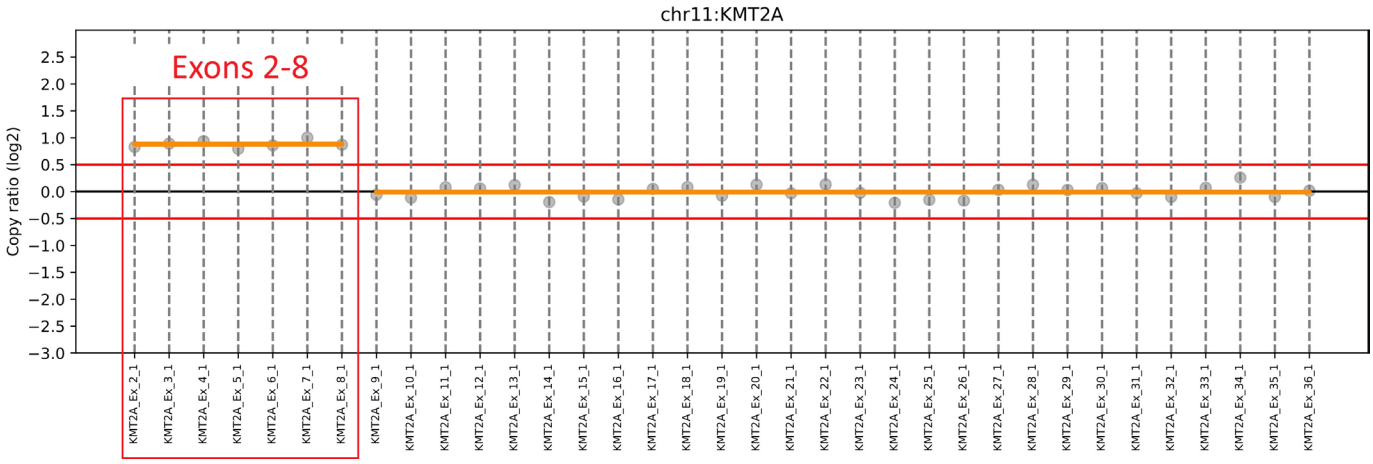

Figure 1 Output from CNVtoolkit shows partial tandem duplication involving exons 2–8 of *KMT2A* gene with log2 values more than 0.5, compared with the rest of the exons with log2 values near zero. Each grey dot represents probes corresponding to the exons as mentioned. CNV, copy number variations.

J Clin Pathol: first published as 10.1136/jcp-2025-210460 on 12 March 2026. Downloaded from http://jcp.bmj.com/ on March 12, 2026 at Duke University Medical Center Library. Protected by copyright, including for uses related to text and data mining, AI training, and similar technologies.

Cytogenetic analysis

Conventional karyotyping and FISH were performed as per standard recommendations.[28] The reports were incorporated from electronic medical records.

End points and statistical analyses

Overall survival (OS) was considered as the primary endpoint and relapse-free survival (RFS) was considered as a secondary endpoint. Patients in whom BM status was not known for documenting remission post-therapy were excluded from statistical analysis. Relapse, OS and RFS were defined using standard definitions.[29] The details are described in supplementary methods (online supplementary figures 4 and 5).

RESULTS

Clinical features of AML with *KMT2A*-PTD

The *KMT2A*-PTD was observed in 41 out of 802 patients of adult AML with an incidence of 5.1%. The median age at diagnosis was 50 years (range 27–76 years) with a male: female ratio of 1:2.4. These cases had a de novo presentation. In addition to these cases, we observed four cases of AML with documented antecedent MDS with *KMT2A*-PTD. The median white blood counts at presentation were 3.2×10^9/L (range: $0.57–122.5\times10^9$/L), median Hb was 76 g/L (range: 45–98 g/L) and median platelet count was 59×10^9/L (range: $5–292\times10^9$/L).

Haematopathology features of de novo AML with *KMT2A*-PTD

Morphologic and immunophenotypic data were available for 39 cases. BM studies were performed in 35 patients, and a diagnosis of AML was made on blood samples in four patients.

Morphological abnormalities

Most patients presented with a hypercellular BM (62.8%), and the most common FAB subtype was AML M1 with a median blast count of 62% (range: 22%–91%). One-third of patients harboured morphologic dyspoiesis (n=14/39, 35.8%). Of these, myeloid lineage dyspoiesis was most common (8/39, 20.5%), followed by erythroid lineage dyspoiesis (3/39, 7.6%). Multilineage dysplasia was observed in a minority of cases (3/39, 7.6%).

Immunophenotypic abnormalities

Progenitor abnormalities: In all cases, abnormal progenitors could be identified with a myeloid lineage immunophenotype. None of the cases harboured aberrant cytoplasmic CD3 or CD79a. Nearly all cases (37 out of 39 cases) demonstrated the presence of CD34 and CD117. As compared with normal progenitors, CD34 was dim (5/37 cases, 13.5%) or bright (1/37 cases, 2.7%) in a fraction but was moderate (15/37 cases, 40.5%) in most cases. Similarly, CD117 was dim (n=1, 2.7%), or bright (n=4, 10.8%) in a minority, but moderate (n=23/37, 62.1%) in most. Additional abnormalities in progenitors included dim or variable HLA-DR (20.5% each), dim or variable CD38 (25.6% and 15.3%, respectively), dim or bright CD33 (12.8% each) and dim or bright CD13 (7.7% each). Dim expression of CD123 (41%), subset expression of CD36 (35.8%), aberrant expression of CD25 (23.5%) and CD86 (52.9%) were also noted. Cross-lineage expression of CD7 was noted in 33.3% of cases, four of which had morphological features of dysplasia. Additional immunophenotypic abnormalities included aberrant CD19 expression (n=6, dim 10.2%) and CD56 (n=2), CD15 (23/39, subset 23%), CD11c (6/34, dim/subset 5.1%), CD11b (7/39, dim 7.6%) and aberrant CD64 expression on CD34 positive progenitors in 51.2% cases (n=20). Few representative plots are shown in figure 2.

Granulocytic abnormalities: Immunophenotypic abnormalities (figure 2) were present in 14/35 cases (40%), including 7 cases in which morphologic dyspoiesis was absent. The most common abnormality detected was asynchronous CD11b versus CD13 versus CD16 maturation pattern in granulocytes (n=14/14). Other abnormalities included loss of side scatter (7/14, 50%), CD15 underexpression (3/14, 21.4%) and loss of CD10 on mature granulocytes (1/14, 7.1%). In addition, CD177 underexpression in CD16-positive neutrophils was seen in 9/14 cases (64.2%). Aberrant CD56 and CD7 expression was present in 7.15% each. A summary of immunophenotypic abnormalities is described in table 1.

Monocytic and erythroid abnormalities: Abnormal maturation pattern of monocytes/aberrant CD56 expression on monocytes was noted in three cases (7.6%). Erythroid abnormalities were evaluated in only five cases, of which four demonstrated underexpression of CD71 (figure 2).

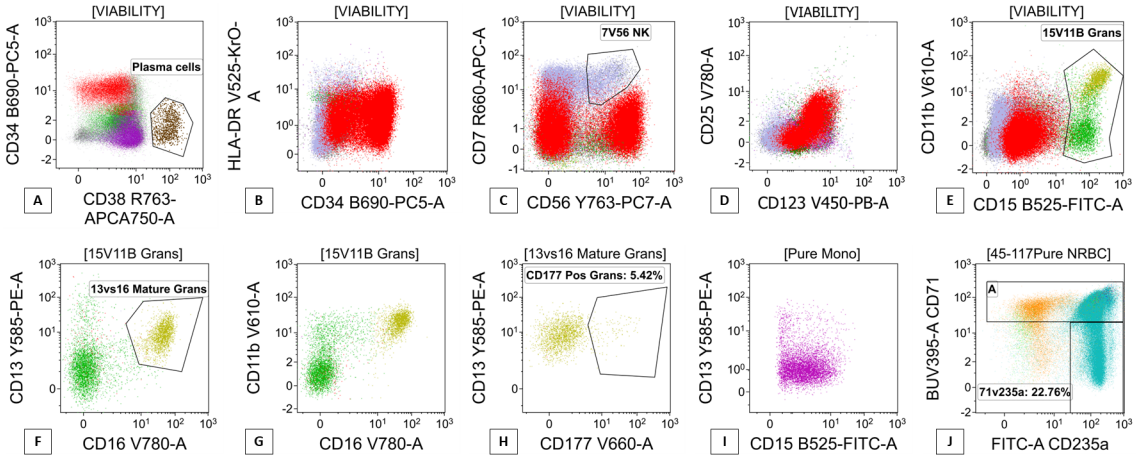

Figure 2 Immunophenotypic abnormalities detected on myeloid blasts (red), maturing granulocytes (green and olive green), monocytes (magenta) and erythroids (orange and cyan): Dim CD38 and Dim HLA-DR on CD34 positive blasts (A, B, respectively). Variable CD7 and partial CD56 expression on myeloid blasts (C). Partial expression of CD123 and CD25 on myeloid blasts (D). Dim CD15 expression on myeloid blasts (E). Granulocytes with abnormal maturation pattern (F, G) and loss of CD177 (H). Monocytes with loss of CD13 (I) and erythroids showing loss of CD71 in CD235a positive population (J). Grans: Granulocytes.

J Clin Pathol: first published as 10.1136/jcp-2025-210460 on 12 March 2026. Downloaded from http://jcp.bmj.com/ on March 12, 2026 at Duke University Medical Center Library. Protected by copyright, including for uses related to text and data mining, AI training, and similar technologies.

Table 1 Immunophenotypic abnormalities of patients harbouring *KMT2A*-PTD

Immunophenotypic abnormalities on progenitors (n=39)	
Markers	**Expression pattern**
Immaturity markers	
CD34 (37/39 cases positive)	Dim: 5/37 (13.5%)
	Moderate: 15/37 (40.5%)
	Bright: 1/37 (2.7%)
CD117 (37/39 cases positive)	Dim: 1/37 (2.7%)
	Moderate: 23/37 (62.1%)
	Bright: 4/37 (10.8%)
Abnormal expression pattern	
HLA-DR	Dim: 8/39 (20.5%)
	Variable: 8/39 (20.5%)
CD38	Dim: 10/39 (25.6%)
	Variable: 6/39 (15.3%)
CD33	Dim: 5/39 (12.8%)
	Bright: 5/39 (12.8%)
CD13	Dim: 3/39 (7.7%)
	Bright: 3/39 (7.7%)
CD123	Dim: 16/39 (41%)
CD36	16/39 (subset, 35.8%)*
CD25	8/34 (dim, 12.8%)*
CD86	18/34 (subset, 20.5%)*
Cross-lineage expression	
CD7	13/39 (subset, 23%)*
CD19	6/39 (dim, 10.2%)*
CD56	2/39
Asynchronous expression	
CD15	23/39 (subset, 23%)*
CD11c	6/34 (dim/subset, 5.1%)*
CD11b	7/39 (dim, 7.6%)*
CD64	20/39 (subset, 30.7%)*
Immunophenotypic evaluation of myeloid maturation (n=14/35)	
Low side scatter of granulocytes	7/14 (50%)
Abnormal CD 11b vs CD13 vs CD16 maturation	14/14 (100%)
CD15 under expression in granulocytes	3/14 cases (21.4%)
CD177 under expression in CD16 positive	9/14 cases (64.2%)
CD56, CD13 over expression, CD10 under expression, CD7 expression in granulocytes	1/14 cases each (7.1%)
Immunophenotypic evaluation of monocytic maturation (n=35)	
Abnormal CD14 vs HLA-DR vs CD64/CD56 expression was seen in 3/39 cases (7.6%)	
Immunophenotypic evaluation of erythroid maturation (n=5)	
CD71 under expression in erythroids was seen in 4/5 cases (80%)	

Abnormal antigen expression pattern included any of the following (1) Overexpression or Underexpression of antigens compared with the template. (2) Asynchronous expression of antigens and (3) cross-Lineage expression of antigens. Any percentage of blasts expressing the antigen was considered positive, with further description of fluorescence intensity commented on.
*Number of samples positive for the marker/total number of samples analysed (common expression pattern, percentage).
PTD, partial tandem duplication.

Genomic features and WHO HAEM5 classification

An oncoplot of mutational spectrum, frequencies and co-mutational landscape can be observed in figure 3. *IDH2* and *FLT3* genes were the most commonly mutated. Nearly 30% of the *IDH2* mutations involved the R172 hotspot. The majority of *FLT3* mutations (77%) were internal tandem duplications. Mutations were also commonly observed in *RUNX1* (29%), *DNMT3A*, *U2AF1* (24% each), *WT1* (20%), *IDH1* (15%), *BCOR, NRAS, TET2* (12% each), *NF1*, *PHF6* (10% each) and *STAG2*, *EZH2* (7% each). AML-defining mutations such as *NPM1*, *CEBPA* or AML-defining fusions such as *RUNX1::RUNX1T1* were absent. The genomic landscape of de novo AML with *KMT2A*-PTD is compared with an unselected adult AML cohort in online supplemental table 5. As per the WHO HAEM5, nearly 56% (n=23/41) and 44% (18/41) cases were classified as AML, defined by differentiation, and 44% (n=18/41) cases were classified as AML-MR, defined by gene mutations or cytogenetics, respectively. PTDs in the *KMT2A* included exons 2–8 (19/41, 46.3%), exons 2–10 (10/41, 24.3%), exons 3–6 (4/41, 9.7%), exons 2–9, 2–12 (2/41, 4.8% each), exons 3–7, 3–8, 3–14, 4–8 (1/41, 2.4% each) (online supplemental figure 2). Cytogenetic assessment (FISH and/or conventional cytogenetics) was performed in 40 patients. Most common abnormality detected by FISH was trisomy 8 (n=5) followed by 7q deletion (n=2), 5q deletion (n=1) and

J Clin Pathol: first published as 10.1136/jcp-2025-210460 on 12 March 2026. Downloaded from http://jcp.bmj.com/ on March 12, 2026 at Duke University Medical Center Library. Protected by copyright, including for uses related to text and data mining, AI training, and similar technologies.

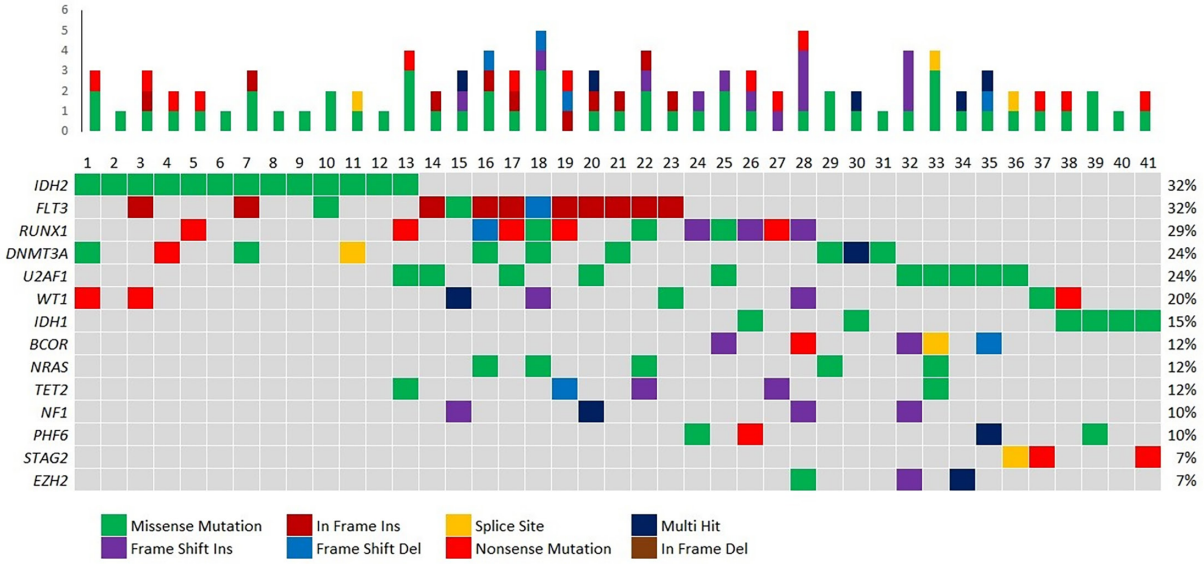

Figure 3 The oncoplot displays mutations across 41 de novo cases of acute myeloid leukaemia with *KMT2A* partial tandem duplication, highlighting mutations with a frequency of more than 5%. The barplot at the top indicates the mutation load per sample.

trisomy 11 (n=1). Of cases in which conventional karyotyping was available (n=14), 85.7% had a normal karyotype. Among the patients classified as AML, defined by differentiation, 10/23 patients showed dyspoiesis either on morphology (n=6) or by immunophenotyping (n=4).

Patient outcomes

As per the ELN 2022 classification, 16/41 (39%) cases belonged to intermediate risk, and 25/41 (61%) cases were adverse risk, which included 18 cases of AML-MR and 7 cases harbouring *RUNX1* mutations. There were no cases of AML with favourable risk. A total of 32 patients received treatment which included either '3+7' intensive chemotherapy (n=13) or 'Azacytidine+Venetoclax' less intensive chemotherapy (n=19). The treatment details of these patients can be seen in online supplemental figure 3). Of the patients in whom therapy responses could be documented (n=27), nearly 29% (n=8) failed to achieve a morphological remission (<5% blasts) post first cycle and among the patients achieving morphologic remission, 60% were FCM-MRD (Flow cytometry-based measurable residual disease) positive (median MRD 0.59%, range 0.09%–4.60%). The median OS and RFS for patients who achieved morphologic remission were 23.03 months (95% CI 16.45 to 29.34 months) and 20.20 months (95% CI 9.93 to 27.66 months), respectively. In the internal comparison within the *KMT2A*-PTD cohort among the patients achieving morphologic remission, the median OS for *KMT2A*-PTD positive AML defined by differentiation and *KMT2A*-PTD positive AML-MR patients was 23.22 months (95% CI 16.81 to 29.34 months) and 16.45 months (95% CI 14.64 to 23.03 months), respectively. Similarly, the median RFS for *KMT2A*-PTD positive AML defined by differentiation and AML-MR patients achieving morphologic remission was 22.27 months (95% CI 8.72 to 27.66 months) and 13.59 months (95% CI 10.69 to 20.20 months), respectively. There was no difference in outcome for OS (p=0.37, HR=1.67 (95% CI 0.54 to 5.20)) and RFS (p=0.87, HR=1.09 (95% CI 0.37 to 3.26)) for patients achieving morphologic remission in AML defined by differentiation and AML-MR, respectively (online supplemental Figure 4A and B). However, the four AML patients with prior history of MDS were either given best supportive care (n=2) or lost to follow-up (n=2) after the diagnosis of AML and therefore were not a part of outcome analysis. Additionally, OS and RFS were compared with an external control AML cohort described in online supplemental Figure 5.

DISCUSSION

We describe morphological and immunophenotypic features of de novo AML with *KMT2A*-PTD and describe the presence of morphological dysplasia in 35.6% and immunophenotypic abnormalities, described in MDS, in 40%. Combined, nearly 50% (n=21) cases harboured abnormalities consistent with dyspoiesis. Furthermore, 44% of AML with *KMT2A*-PTD could be diagnosed as AML-MR based on cytogenetics or genomics. Although we have limited numbers, we demonstrate similar outcomes of AML with *KMT2A*-PTD with or without MR associated abnormalities. Given the fact that this abnormality is not only described in MDS but is also a part of the Molecular International Prognostic Scoring System for Myelodysplastic Syndromes, it is perhaps prudent to consider this as an AML, MR-associated abnormality.[30] This paper is the first study to describe the immunophenotypic abnormalities of myeloid blasts and the dyspoietic patterns seen in granulocytes and erythroids. We also describe the mutational landscape and outcome of AML patients harbouring *KMT2A*-PTD.

The seminal paper by Coleman-Lindsley described mutations in eight genes that were found to be highly specific for secondary AML. These genes were included in WHO HAEM5 as well as the International Consensus Classification as a criteria for diagnosing AML-MR in addition to cytogenetic abnormalities.[31 32] However, the paper did not analyse the *KMT2A* gene for sequence abnormalities, fusions or copy number alterations. It is highly likely that the role of *KMT2A*-PTD in the ontogeny of secondary AML was overlooked.

The median age at diagnosis of AML patients harbouring *KMT2A*-PTDs was 50 years (range 27–76 years), which is much older than our previously published cohort of AML patients with a median age of 35 and 36 years (range 18–63 years).[21 23] The incidence of *KMT2A*-PTD was 5.1% in our study, similar to other published studies with incidences ranging from 3.2% to 11%.[7 9 15 16]

J Clin Pathol: first published as 10.1136/jcp-2025-210460 on 12 March 2026. Downloaded from http://jcp.bmj.com/ on March 12, 2026 at Duke University Medical Center Library. Protected by copyright, including for uses related to text and data mining, AI training, and similar technologies.

In this study, we describe the progenitor abnormalities in *KMT2A*-PTD which overlap with progenitor abnormalities described in MDS.[33–37] Among these, CD7 expression on myeloid blasts is described at a frequency of ~20%–32% of MDS cases, compared with 33.3% of our cases.[35 36] CD15 expression in myeloid blasts was seen in 59% of our cases compared with a frequency of 56%–95% in MDS.[37] Although CD7 and CD15 expression is seen in de novo AMLs, they are frequently associated with *CEBPA* mutations, which were absent in our cohort.[38] Shiah *et al* have described CD11b expression on myeloid blasts in ~75% cases of AML with *KMT2A*-PTD with normal karyotype.[10] Contrastingly, only 7/39 (18%) cases expressed CD11b on myeloid blasts in our cohort.

In addition to progenitor abnormalities in MDS, abnormal antigen expression in granulocytic, monocytic and erythroid lineages is also described in the literature.[33–36 39] We found immunophenotypic dyspoiesis in 14/35 cases (40%). Low SSC of granulocytes is described at frequencies from 8 to 84% in MDS different studies compared with 7/14 (50%) cases with immunophenotypic dyspoiesis in our cohort. Abnormal CD11b versus CD13 versus CD16 pattern in granulocytes was a common finding in our study. Aberrant CD56 expression on monocytes was rare. Erythroid dyspoiesis was evaluated in only five of our cases, and four of them had underexpression of CD71 in CD235a positive population compared with ~60% cases of MDS.[39]

Mutational landscape of AML harbouring *KMT2A* PTDs is described in the literature with mutations seen in genes involved in signalling pathways (*FLT3*-ITD, *NRAS, KRAS,* etc), epigenetic regulators (*DNMT3A, TET2, IDH1/2,* etc), transcription factors (*RUNX1,* etc).[6 9 14 15] We demonstrate that MR-associated mutations are enriched in AML with *KMT2A*-PTD. Our study also had similar results with mutations in *IDH2*, *FLT3* (32% each) being the most common followed by *RUNX1* (29%) and *DNMT3A, U2AF1* (24%) genes. Also, mutations in genes associated with AML-MR were noted in 43.9% of cases. Interestingly, there were no cases with defining molecular abnormalities such as *NPM1* mutation and bZIP-mutated *CEBPA* found in our study. The mutational profile of patients in our study is similar to the published literature.[6 9 14 15] In *IDH2* mutated cases, the mutations involved both of the known hotspots widely described, which are p.(Arg140) (69.2% of cases) and p.(Arg172) (30.7% of cases). ITDs were the most common mutations in the *FLT3* gene, corresponding to 77% of *FLT3*-mutated cases. Our cytogenetic results match the published literature wherein AML harbouring *KMT2A* PTDs predominantly co-occur with normal karyotype (87.5% patients in our cohort); however, only one patient had trisomy 11 in our cohort.[7 14 15]

Although we have limited sample size, we also explored the outcomes of AML patients with *KMT2A*-PTD achieving morphologic remission and found that the median OS and RFS were 23.03 months (95% CI 16.45 to 29.34 months) and 20.20 months (95% CI 9.93 to 27.66 months), respectively. Outcome analysis, however, is not the primary goal of this manuscript. For comparison, the median OS and RFS for AML patients with poor cytogenetic risk were comparable in our previous cohort (Gojiri *et al JCO Glob. Oncol*. 2025)[21] (online supplemental Data). For the patients who achieved morphologic remission, there was no difference in outcome for OS (p=0.37, HR=1.67 (95% CI 0.54 to 5.20)) and RFS (p=0.87, HR=1.09 (95% CI 0.37 to 3.26)) of AML defined by differentiation compared with AML-MR. Recently, a meta-analysis that included 18 studies covering 6499 patients with AML showed that patients harbouring *KMT2A*-PTD had shorter OS in the total population (HR 1.3) and poor event-free survival (HR 1.34).[13] Other studies have also concluded that older age (>50 years), *DNMT3A* and *NRAS* mutations were associated with inferior outcomes in patients harbouring *KMT2A*-PTD.[14 15]

We have described the morphologic, immunophenotypic dyspoiesis and the correlation with AML-MR including the MR mutations described in the WHO HAEM5 in AML patients harbouring *KMT2A*-PTD. The drawbacks of our study include a relatively small size of the cohort, a potential bias while excluding patients with unknown remission status, lack of uniform treatment and lack of erythroid lineage immunophenotyping in all patients. We demonstrate that AML harbouring *KMT2A*-PTD frequently displays myelodysplasia associated immunophenotypic abnormalities in both precursors and maturing cells. Additionally, they are frequently associated with AML-MR type mutations and have similar outcomes as compared with AML-MR. Further genetic and biological studies that examine the presence of *KMT2A*-PTD in secondary AML are required to confirm these findings.

Handling editor Kikkeri N Naresh.

Acknowledgements We would like to thank the clinical trial coordinators and the technical team for performing flow and NGS experiments.

Contributors NP and NKannan designed the study, conducted research, analysed, interpreted the data and wrote the manuscript. AA, VT, VG, SJ, PB, SC, PS, SG, ND and DS conducted research and analysed data. PT, SR, GC and PGS conducted research and analysed data. AS, SM, LN, AG, SP, HJ, BB, MS and NKhattry recruited patients and analysed data. NP is the guarantor.

Funding This work was supported by the DBT Wellcome Trust India Alliance Senior Fellowship (grant number IA/CPHS/21/1/505947) awarded to NP and Indian Council of Medical Research Grant No: 5/13/9/NP/ICRC/2020/NCD-III.

Competing interests None declared.

Patient consent for publication Not applicable.

Provenance and peer review Not commissioned; externally peer reviewed.

Data availability statement Data are available on reasonable request.

Supplemental material This content has been supplied by the author(s). It has not been vetted by BMJ Publishing Group Limited (BMJ) and may not have been peer-reviewed. Any opinions or recommendations discussed are solely those of the author(s) and are not endorsed by BMJ. BMJ disclaims all liability and responsibility arising from any reliance placed on the content. Where the content includes any translated material, BMJ does not warrant the accuracy and reliability of the translations (including but not limited to local regulations, clinical guidelines, terminology, drug names and drug dosages), and is not responsible for any error and/or omissions arising from translation and adaptation or otherwise.

ORCID iDs
Narasimhapriyan Kannan https://orcid.org/0000-0003-3688-965X
Dhanlaxmi Shetty https://orcid.org/0000-0003-2083-3176
Papagudi G Subramanian https://orcid.org/0000-0001-9107-5937
Nikhil Patkar https://orcid.org/0000-0001-9234-2857

REFERENCES

1 Krivtsov AV, Armstrong SA. MLL translocations, histone modifications and leukaemia stem-cell development. *Nat Rev Cancer* 2007;7:823–33.
2 Meyer C, Larghero P, Almeida Lopes B, *et al*. The KMT2A recombinome of acute leukemias in 2023. *Leukemia* 2023;37:988–1005.
3 Döhner H, Wei AH, Appelbaum FR, *et al*. Diagnosis and management of AML in adults: 2022 recommendations from an international expert panel on behalf of the ELN. *Blood* 2022;140:1345–77.
4 Steudel C, Wermke M, Schaich M, *et al*. Comparative analysis of MLL partial tandem duplication and FLT3 internal tandem duplication mutations in 956 adult patients with acute myeloid leukemia. *Genes Chromosomes Cancer* 2003;37:237–51.
5 Dicker F, Haferlach C, Sundermann J, *et al*. Mutation analysis for RUNX1, MLL-PTD, FLT3-ITD, NPM1 and NRAS in 269 patients with MDS or secondary AML. *Leukemia* 2010;24:1528–32.
6 Sun Q-Y, Ding L-W, Tan K-T, *et al*. Ordering of mutations in acute myeloid leukemia with partial tandem duplication of MLL (MLL-PTD). *Leukemia* 2017;31:1–10.
7 Basecke J, Whelan JT, Griesinger F, *et al*. The MLL partial tandem duplication in acute myeloid leukaemia. *Br J Haematol* 2006;135:438–49.

J Clin Pathol: first published as 10.1136/jcp-2025-210460 on 12 March 2026. Downloaded from http://jcp.bmj.com/ on March 12, 2026 at Duke University Medical Center Library. Protected by copyright, including for uses related to text and data mining, AI training, and similar technologies.

8 Issa GC, Ravandi F, DiNardo CD, *et al*. Therapeutic implications of menin inhibition in acute leukemias. *Leukemia* 2021;35:2482–95.
9 Wei Q, Hu S, Xu J, *et al*. Detection of *KMT2A* Partial Tandem Duplication by Optical Genome Mapping in Myeloid Neoplasms: Associated Cytogenetics, Gene Mutations, Treatment Responses, and Patient Outcomes. *Cancers (Basel)* 2024;16:4193.
10 Shiah H-S, Kuo Y-Y, Tang J-L, *et al*. Clinical and biological implications of partial tandem duplication of the MLL gene in acute myeloid leukemia without chromosomal abnormalities at 11q23. *Leukemia* 2002;16:196–202.
11 Schnittger S, Kinkelin U, Schoch C, *et al*. Screening for MLL tandem duplication in 387 unselected patients with AML identify a prognostically unfavorable subset of AML. *Leukemia* 2000;14:796–804.
12 Döhner K, Tobis K, Ulrich R, *et al*. Prognostic significance of partial tandem duplications of the MLL gene in adult patients 16 to 60 years old with acute myeloid leukemia and normal cytogenetics: a study of the Acute Myeloid Leukemia Study Group Ulm. *J Clin Oncol* 2002;20:3254–61.
13 Ye W, Ma M, Wu X, *et al*. Prognostic significance of *KMT2A*-PTD in patients with acute myeloid leukaemia: a systematic review and meta-analysis. *BMJ Open* 2023;13:e062376.
14 Kao H-W, Liang DC, Kuo M-C, *et al*. High frequency of additional gene mutations in acute myeloid leukemia with MLL partial tandem duplication: DNMT3A mutation is associated with poor prognosis. *Oncotarget* 2015;6:33217–25.
15 Hinai ASAA, Pratcorona M, Grob T, *et al*. The Landscape of *KMT2A*-PTD AML: Concurrent Mutations, Gene Expression Signatures, and Clinical Outcome. *Hemasphere* 2019;3:e181.
16 Seto A, Downs G, King O, *et al*. Genomic Characterization of Partial Tandem Duplication Involving the *KMT2A* Gene in Adult Acute Myeloid Leukemia. *Cancers (Basel)* 2024;16:1693.
17 Choi SM, Dewar R, Burke PW, *et al*. Partial tandem duplication of *KMT2A (MLL)* may predict a subset of myelodysplastic syndrome with unique characteristics and poor outcome. *Haematologica* 2018;103:e131–4.
18 Khoury JD, Solary E, Abla O, *et al*. The 5th edition of the World Health Organization Classification of Haematolymphoid Tumours: Myeloid and Histiocytic/Dendritic Neoplasms. *Leukemia* 2022;36:1703–19.
19 Patkar N, Kodgule R, Kakirde C, *et al*. Clinical impact of measurable residual disease monitoring by ultradeep next generation sequencing in *NPM1* mutated acute myeloid leukemia. *Oncotarget* 2018;9:36613–24.
20 Patkar N, Shaikh AF, Kakirde C, *et al*. A novel machine-learning-derived genetic score correlates with measurable residual disease and is highly predictive of outcome in acute myeloid leukemia with mutated NPM1. *Blood Cancer J* 2019;9:79.
21 Patkar N, Kakirde C, Bhanshe P, *et al*. Utility of Immunophenotypic Measurable Residual Disease in Adult Acute Myeloid Leukemia-Real-World Context. *Front Oncol* 2019;9:450.
22 Shaikh AF, Kakirde C, Dhamne C, *et al*. Machine learning derived genomics driven prognostication for acute myeloid leukemia with *RUNX1-RUNX1T1*. *Leuk Lymphoma* 2020;61:3154–60.
23 Patkar N, Kakirde C, Shaikh AF, *et al*. Clinical impact of panel-based error-corrected next generation sequencing versus flow cytometry to detect measurable residual disease (MRD) in acute myeloid leukemia (AML). *Leukemia* 2021;35:1392–404.
24 Talevich E, Shain AH, Botton T, *et al*. CNVkit: Genome-Wide Copy Number Detection and Visualization from Targeted DNA Sequencing. *PLoS Comput Biol* 2016;12:e1004873.
25 Komrokji RS, Lanino L, Ball S, *et al*. Data-driven, harmonised classification system for myelodysplastic syndromes: a consensus paper from the International Consortium for Myelodysplastic Syndromes. *Lancet Haematol* 2024;11:e862–72.
26 Zampini M, Riva E, Lanino L, *et al*. Characterization and Clinical Implications of p53 Dysfunction in Patients With Myelodysplastic Syndromes. *J Clin Oncol* 2025;43:2069–83.
27 Patkar N, Bhanshe P, Rajpal S, *et al*. NARASIMHA: Novel Assay based on Targeted RNA Sequencing to Identify ChiMeric Gene Fusions in Hematological Malignancies. *Blood Cancer J* 2020;10:50:50:.
28 Korf BR. Overview of clinical cytogenetics. *Curr Protoc Hum Genet* 2001.
29 Cheson BD, Bennett JM, Kopecky KJ, *et al*. Revised Recommendations of the International Working Group for Diagnosis, Standardization of Response Criteria, Treatment Outcomes, and Reporting Standards for Therapeutic Trials in Acute Myeloid Leukemia. *JCO* 2003;21:4642–9.
30 Bernard E, Tuechler H, Greenberg PL, *et al*. Molecular International Prognostic Scoring System for Myelodysplastic Syndromes. *NEJM Evid* 2022;1.
31 Lindsley RC, Mar BG, Mazzola E, *et al*. Acute myeloid leukemia ontogeny is defined by distinct somatic mutations. *Blood* 2015;125:1367–76.
32 Arber DA, Orazi A, Hasserjian RP, *et al*. International Consensus Classification of Myeloid Neoplasms and Acute Leukemias: integrating morphologic, clinical, and genomic data. *Blood* 2022;140:1200–28.
33 Wells DA, Benesch M, Loken MR, *et al*. Myeloid and monocytic dyspoiesis as determined by flow cytometric scoring in myelodysplastic syndrome correlates with the IPSS and with outcome after hematopoietic stem cell transplantation. *Blood* 2003;102:394–403.
34 van de Loosdrecht AA, Alhan C, Béné MC, *et al*. Standardization of flow cytometry in myelodysplastic syndromes: report from the first European LeukemiaNet working conference on flow cytometry in myelodysplastic syndromes. *Haematologica* 2009;94:1124–34.
35 Westers TM, Alhan C, Chamuleau MED, *et al*. Aberrant immunophenotype of blasts in myelodysplastic syndromes is a clinically relevant biomarker in predicting response to growth factor treatment. *Blood* 2010;115:1779–84.
36 van de Loosdrecht AA, Westers TM, Westra AH, *et al*. Identification of distinct prognostic subgroups in low- and intermediate-1-risk myelodysplastic syndromes by flow cytometry. *Blood* 2008;111:1067–77.
37 Ogata K, Nakamura K, Yokose N, *et al*. Clinical significance of phenotypic features of blasts in patients with myelodysplastic syndrome. *Blood* 2002;100:3887–96.
38 Lin L-I, Chen C-Y, Lin D-T, *et al*. Characterization of CEBPA mutations in acute myeloid leukemia: most patients with CEBPA mutations have biallelic mutations and show a distinct immunophenotype of the leukemic cells. *Clin Cancer Res* 2005;11:1372–9.
39 Stetler-Stevenson M, Arthur DC, Jabbour N, *et al*. Diagnostic utility of flow cytometric immunophenotyping in myelodysplastic syndrome. *Blood* 2001;98:979–87.

J Clin Pathol: first published as 10.1136/jcp-2025-210460 on 12 March 2026. Downloaded from http://jcp.bmj.com/ on March 12, 2026 at Duke University Medical Center Library. Protected by copyright, including for uses related to text and data mining, AI training, and similar technologies.